

## Acquired Lymphangiectasia of the Scrotum: A Case Report

Abdullah Mancy\*

*Department of Dermatology, Al-Ramadi Teaching Hospital, Anbar Health Directorate, Ramadi, Anbar, Iraq*

(Received : 25 August 2019; Accepted : 17 October 2019; First published online: 22 October 2019)

### ABSTRACT

The majority of cutaneous lymphangiomas are congenital in origin. Occasionally they arise from acquired lymphatic obstruction. The scrotum is rarely subjected to lymphatic malformations. These affecting the scrotum usually present with multiple, translucent, thick-walled vesicles, at times their surfaces are verrucous which may be mistaken for genital warts, and frequently consist of a combination of blood and lymph elements that may be confused with vascular tumors such as angiokeratomas. Idiopathic acquired lymphangiectasia is seldom registered as a reported case in the literature. We reported a further case of acquired lymphangiectasia of the scrotum in a 27-year old male without any obvious predisposing factor.

**Keywords:** Lymphedema, Scrotum, Lymphangiectasia, Verrucous, Lymphangioma.

DOI: [10.33091/AMJ.0801522019](https://doi.org/10.33091/AMJ.0801522019)

© 2019, Al-Anbar Medical Journal



### INTRODUCTION

Superficial lymphatic malformations, the old term for this was lymphangioma circumscriptum, are a group of benign lesions involving the dermal and/or subcutaneous lymphatic channels. They typically present as groups of deep-seated vesicles-like papules resembling frog spawn, at birth or shortly thereafter. The sites of predilection are the abdomen, axillae, genitalia, and mouth particularly the tongue [1].

Acquired malformations are rare and usually develop secondary to radiotherapy, infections or surgery. These malformations affecting the scrotum are infrequent. The occurrence of late-onset lymphangioma circumscriptum after obstruction of the lymphatics is called acquired lymphangiectasia [2].

Lymphedema result from an accumulation of proteins and water in the tissues due to damaged lymphatic vessels, in association with inflammatory cells, will convert the swollen tissue into hard fibrotic with hyperkeratotic skin [3].

### CASE PRESENTATION

A 27- year old non-obese gentleman presented to the outpatient Dermatology Department of Al- Ramadi Teaching Hospital complaining of swollen scrotum associated with multiple warty papules for 10 years. On examination, there were

multiple, discrete and/or coalescing verrucous, whitish to the skin-colored papules, nodules and thick-walled vesicles on the scrotum Figure 1.

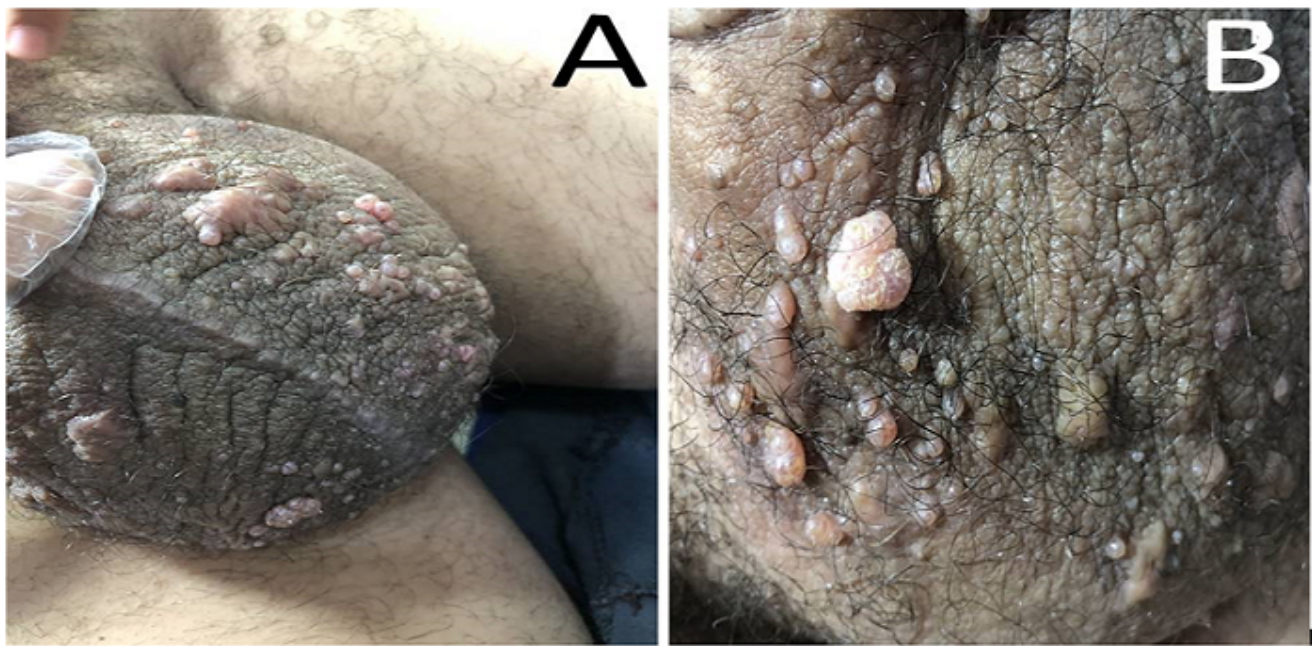
There was no history of trauma, previous surgical operation, past medical diseases, infections in that site, or a history of topical drug application. He had a normal laboratory test. Ultrasound examination reveals both epididymides are normal in size and texture, severely thickened and edematous skin, no abscess collection. A punch biopsy was taken from thick-walled vesicle and sent for histopathological examination Figure 2. The benefit of the immunohistochemistry tests is to differentiate between hemangiomas and lymphangiomas in difficult situations, but these tests are not available in our locality.

A diagnosis of cutaneous lymphangiectasia was made based on clinical history, physical and histopathological findings. We referred the patient to Urologist for further treatment. Ethical approval was obtained from the scientific committee of our hospital. Informed consent was taken from the patient for publication of his case.

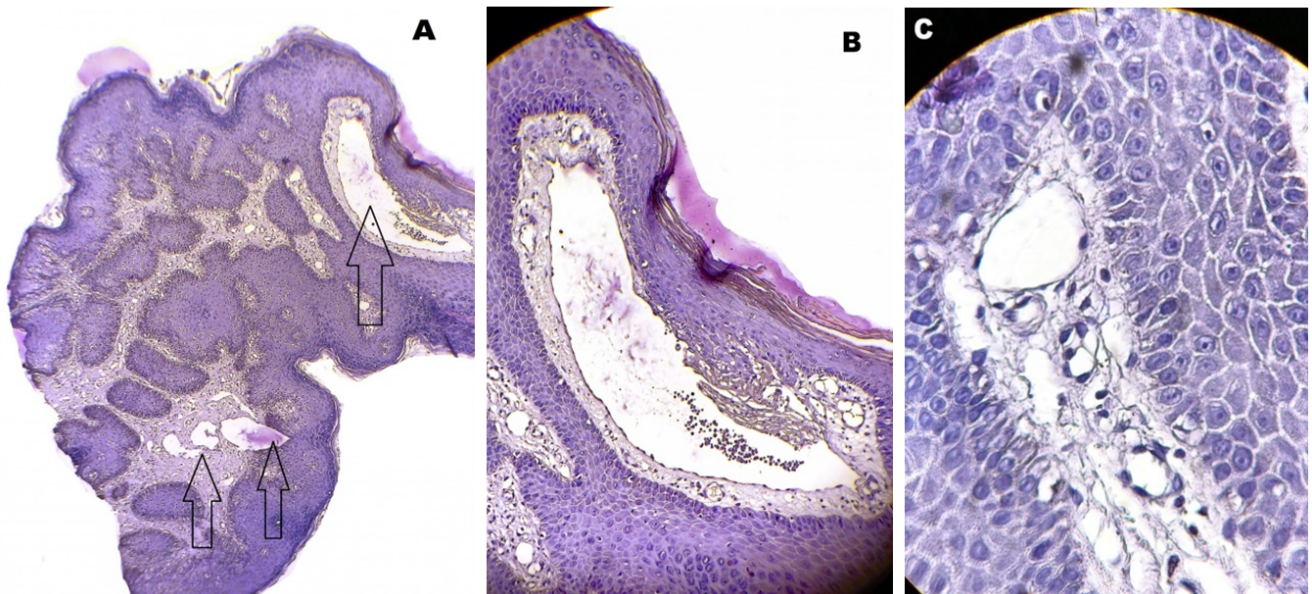
### DISCUSSION

Lymphangioma is a benign proliferation of the lymphatic system. It occurs in the first years of life or sometimes later, as a congenital defect, or could be acquired, secondary to obstruction of the lymphatic vessels that result from radiation, surgery, malignancy, trauma, or infections such as filariasis, tuberculosis, lymphogranuloma venereum [4–6].

\* Corresponding author: E-mail: [abdmancy@yahoo.com](mailto:abdmancy@yahoo.com)  
Phone number: +9647831056564



**Figure 1.** [A & B(close up view)]: A 27-years-old man complaining of lymphedema of the scrotum in association with multiple warty papules and thick-walled vesicles.



**Figure 2.** Histopathological examination of thick-walled vesicle reveals variable-sized vascular spaces lined by thin endothelial layer, and some containing eosinophilic fluid in association with hyperkeratosis and hypergranulosis of the epidermis. [hematoxylin and eosin stain,A:64X, B:160X and C:640X ].

The pathogenesis of superficial lymphatic malformations was postulated to be a group of subcutaneous cysts that develop in utero. These cysts are not in contact with the lymphatic system. So they are not able to drain the lymph from neighboring tissues. They are lined with muscles that contract and by applying pressure produce protrusions in the skin [7].

Acquired malformations are rare and are infrequently af-

fecting the scrotum. Their clinical presentation may vary from clear vesicles, papules, nodules and, warty lesions. So they could be mistaken for genital wart, herpes simplex, molluscum contagiosum, tuberculosis verrucosa cutis, but these diseases can be excluded by their specific features.

Clinical diagnosis of these malformations must be confirmed by histopathological examination. The presence of deep irregular lymphatics beneath the surface vessels in lym-

phangioma circumscrip-tum, a feature differentiating it from acquired lymphangiectasis [2]. In the study case, dilated lymphatic channels mostly apparent histopathologically limited to the superficial dermis, and this in favor of acquired lesion.

The incidence of lymphangioma occurs mainly at birth or early in life [8]. Scrotal lymphangioma is a rare tumor, in spite of several reported cases which has been mentioned in the kinds of literature [7, 9]. Acquired lymphangiectasis of the glans has been reported after circumcision [10]. Those of the vulva may be associated with pregnancy [11]. Acquired lesions may also occur at the sites of chronic high-potency steroids application and in association with chronic lymphedema [1, 12]. This chronic lymphedema could be idiopathic without an apparent cause [13, 14].

In the present case, there was no history of previous surgery, diseases, and topical drugs application apart from

chronic scrotal lymphedema. So the presence of scrotal lymphedema for a long duration may contribute to the lymphatic obstruction. This may result in the appearance of skin lesions.

The lesion in our case was present for 10 years, where history and investigations failed to pinpoint any associated cause, it seems to be an acquired lesion that may be due to chronic lymphedema which most probably of an idiopathic type.

## CONCLUSION

To keep in mind that the development of lymphatic malformations of the scrotum can occur in an adult patient, so correct diagnosis and prevention of inappropriate treatment to the patients will be done.

## CONFLICT OF INTEREST

The author declare that there is no conflict of interest.

## REFERENCES

- [1] W.D. James, T.G. Berger, and D.M. Elstone. Dermal and subcutaneous tumors in: Andrews diseases of the skin. *Clinical Dermatology*, 12th ed. Philadelphia. WB Saunders Company, pages 659–711, 2016.
- [2] K. Chatterjee, V. N. Sehgal, S. Koley, A. C. Patra, G. Chatterjee, and A. Chaudhuri. Acquired lymphangiectasia of the scrotum. *Skinmed*, 16(5):337–339, 2018.
- [3] S. Lu et al. Localized lymphedema (elephantiasis): a case series and review of the literature. *J. Cutan. Pathol.*, 36(1):1–20, 2009.
- [4] S. Arya, A. Nyati, and M. L. Bunkar. Cutaneous lymphangiectasia of genitalia: A rare occurrence. *J. Assoc. Physicians India*, 66:60, 2018.
- [5] S. R. Chintagunta and G. Arakkal. Lymphangiectasia of varied etiology: Case series. *J. Dr. NTR Univ. Heal. Sci.*, 8(2):125, 2019.
- [6] N. Khunger. Combination technique of radiofrequency ablation with sclerotherapy in acquired lymphangiectasis of the vulva. *J. Cutan. Aesthet. Surg.*, 2(1):33, 2009.
- [7] S. Haroon and S. H. Hasan. Lymphangioma circumscrip-tum in the scrotum: a case report. *J. Med. Case Rep.*, 6(1):233, 2012.
- [8] A. O. Ersoy, E. Oztas, E. Saridogan add S. Ozler, and N. Danisman. An unusual origin of fetal lymphangioma filling right axilla. *J. Clin. diagnostic Res. JCDR*, 10(3):QD09, 2016.
- [9] R. Wong, M. Melnyk, S. S. Tang, and C. Nguan. Scrotal lymphangiomatosis: a case report. *Can. Urol. Assoc. J.*, 6(6):E11, 2012.
- [10] R. Zhang, Y. Yang, and W. Zhu. Acquired lymphangiectasia of the glans following circumcision. *JDDG J. der Dtsch. Dermatologischen Gesellschaft*, 12(7):623–624, 2014.
- [11] S. Verma. Pregnancy-induced lymphangiectasias of the vulva. *Int. J. STD AIDS*, 19(3):211–212, 2008.
- [12] J. P. Bandino, C. M. Hivnor, and W. C. Cragun. What is your diagnosis? acquired cutaneous lymphangiectasia. *Cutis*, 90(6):283–291, 2012.
- [13] E. Zacharakis, T. Dudderidge, and E. Ioannidis. Surgical repair of idiopathic scrotal elephantiasis. *South. Med. J.*, 101(2):208–210, 2008.
- [14] C. Dianzani et al. Giant scrotal elephantiasis: an idiopathic case. *Int. J. Immunopathol. Pharmacol*, 23(1):369–372, 2010.