

## Corpus Callosum-Complete Agenesis

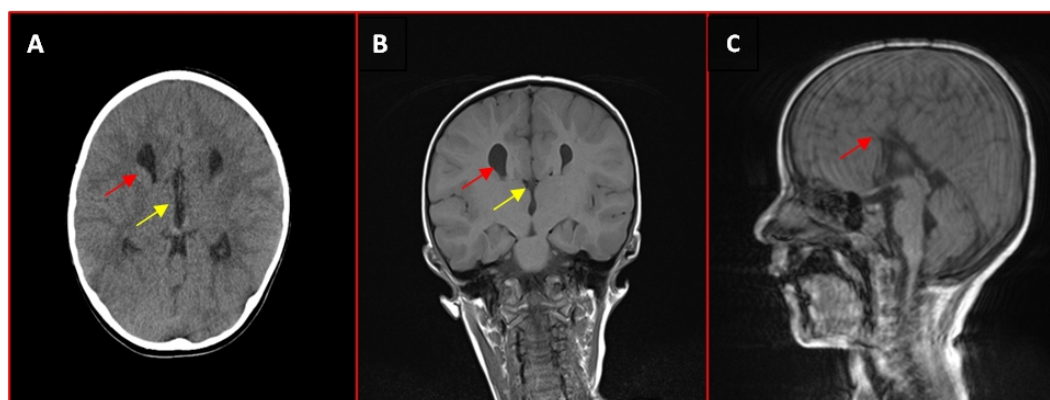
Ghassan M. Khalaf\*

Department of Radiology, Al-Ramadi Maternity and Children Teaching Hospital, Anbar Health Directorate, Ramadi, Anbar, Iraq

(Received : 15 July 2019; Accepted : 25 October 2019; First published online: 27 October 2019)

DOI: [10.33091/AMJ.0901522019](https://doi.org/10.33091/AMJ.0901522019)

© 2019, Al-Anbar Medical Journal



**A** 5-years-old male child referred by the pediatrician for brain computerized tomography (CT) scan as he complains from a delayed milestone. Axial CT [panel A showing, racing car sign, the two lateral ventricles resemble tires (red arrow), and the third ventricle represents the body of Formula One car seen from above (yellow arrow)]. The findings suggest complete corpus callosum agenesis (CCA) which is further confirmed by brain magnetic resonance imaging (MRI). Coronal MRI [panel B, give a moose head sign with the third ventricle representing the moose's actual head (yellow arrow), and the lateral ventricles the horns (red arrow)]. Sagittal MRI [panel C, showing the absence of corpus callosum (red arrow)]. The corpus callosum is the largest nerve fibers in the brain composed of a million thick band of nerve fibers and connects both brain hemispheres. It has many functions like movement of the eyes and vision, maintenance of balance and attention, and tactile localization. CCA or dysgenesis is a congenital malformation that may be an isolated finding or associated with other CNS or systemic anomalies. It may be complete, partial or atypical forms. Also, it may be primary (no other brain tissue degeneration) or secondary (due to brain degeneration). CCA is the most frequent brain anomalies in an incidence of 0.5- 70 in 10,000 with a male predilection (male: female-2:1).

\* Corresponding author: E-mail: [gmk83f@yahoo.com](mailto:gmk83f@yahoo.com)  
Phone number: +9647705223390