

3D Reconstruction of Mandibular Defects using CAD/CAM Designed Zirconia Prosthesis

Kamal T. Aftan*

Department of Oral and Maxillofacial Surgery, College of Dentistry, University of Anbar, Ramadi, Anbar, Iraq
(Received : 2 June 2019; Accepted : 6 July 2019; First published online: 8 July 2019)

ABSTRACT

Background: Reconstruction of mandibular defects with autogenous free bone graft is considered the preferred method. However, the optimum reconstruction technique of mandibular defects is still controversial.

Objectives: To assess the efficacy and safety of the zirconia individual designed CAD/CAM prosthesis for the mandibular reconstruction.

Materials and methods: We used a new method (zirconia prosthesis) for the reconstruction of mandibular defects due to various causes. The study was carried out in the Oral and Maxillofacial Department of Al-Ramadi Teaching Hospital during a period of 62 months from January 2012 to March 2017. Data were collected for each patient regarding the age, gender, site and cause of the defect, investigations, operative technique, complications, outcome, and the duration of the follow-up.

Results: Twenty patients, 14 were men and 6 women; the patients' ages ranged from 19 to 70 years. The majority of the defects were caused by tumors, while, 40% due to congenital or traumatic causes. The success rate of the prosthesis taking was 95%. And in these cases, esthetic and functional outcomes were restored or improved after the reconstruction in all subjects.

Conclusion: We described a novel method for mandibular reconstruction with zirconium individual-designed CAD/CAM model. We advise to use this method owing to the high success rate, the less major rate of complications in comparison with other methods, and high rate of functional and esthetic outcome.

Keywords: Mandible, Reconstruction, Graft, Zirconia, CAD/CAM system, Bowerman Conroyd appliance.

DOI: [10.33091/AMJ.0201522019](https://doi.org/10.33091/AMJ.0201522019)

© 2019, Al-Anbar Medical Journal



INTRODUCTION

Maxillofacial defects are caused by numerous causes that may be congenital, traumatic, neoplastic or iatrogenic such as tumor ablation [1, 2]. Mandibular continuity defects causes both esthetic and functional abnormalities. There is limitation in protrusive and lateral movement of the jaw and mid-line asymmetry. Moreover, malocclusion and proprioception problems may occur [3, 4]. The goals for a successful reconstruction of the mandible are to establish the continuity and

restore the height, width and form of dental arch and improve the facial contour and profile [5]. Historically, autogenous bone graft was the gold standard technique for the reconstruction of the mandibular defects [6]. The non-vascularized autogenous bone may be harvested from local and distant sites and their success rate were well-established [7]. The use of non-vascularized bone grafts is compromised in certain conditions which include the following: (1) difficult mandibular reconstructions where there is an extensive bony defect and soft tissue coverage is insufficient, (2) where the recipient graft bed has been compromised by radiotherapy, previous surgery or chronic infection. In the last 30 years, however, reconstruction of the mandibular defects by the vascularized bone grafts has become popular. The fibular osteocutaneous free flap becomes the gold standard donor site for mandibu-

* Corresponding author: E-mail: drkta73@gmail.com
Phone number: +9647737771076

lar reconstruction. Several studies reported flap survival rate greater than 95% with skin paddle viability over 90% of cases [8, 9]. The importance of CAD/CAM in surgery is well established to overcome the disadvantages and limitations of conventional methods by creating precise 3-dimensional image of bony defects and reduce the errors associated with traditional procedures.

Numerous alloplastic grafts and devices were used in reconstruction of mandible such as medpore, reconstruction plate and modular Endo-prosthesis with variable and unpredictable results [10, 11]. Zirconia is one of the biocompatible graft materials and has many applications in oral surgery such as zirconia implant [12]. The results from zirconium proved significantly superior to those obtained from the use of non-vascular options such as reconstruction plates and bone grafts [13].

The aim of this study was to assess the efficacy and safety of new modality for mandibular reconstruction which is zirconia individual designed CAD/CAM prosthesis.

MATERIALS AND METHODS

The study carried out between January 2012 and March 2017, we introduced zirconia individual-designed CAD/CAM Prosthesis for reconstruction of a mandibular defect due to various causes. Patients with benign aggressive mandibular tumors such as ameloblastoma, odontogenic myxoma and pindborg tumor, traumatic defects or congenital deformity such as microgenia or condylar hypoplasia who visiting the consultation clinic of the Department of Oral and Maxillo-facial Surgery in Al-Ramadi Teaching Hospital, Anbar, Iraq, which require surgical resection and/or reconstruction of the mandible, were enrolled in the study. While, patients with malignant tumors of mandible such as squamous cell carcinoma, previous or anticipated radiotherapy were excluded from the present study. Informed consent was taken from every subject. The current study approved by the College of Dentistry, University of Anbar.

For each case, we registered the following: age of the patient, gender, cause of the defect, preoperative deformity like in Figure 1 A and B, pre-and post-operative radiological findings as in Figure 1 C and D, results of biopsy in case of tumor, site of the mandibular defect, range of mandibular resection, operative timing of resection and/or reconstruction, outcome concerning the success rate, functional and aesthetic outcome, complications, and follow-up period. For the purpose of the study, facial contour regarded: good (facial contour and profile accepted by surgeon and patient), adequate (facial contour and profile accepted by patient only), and Poor (facial contour and profile are unsatisfactory from both the patient and surgeon).

For those patients with tumors, the surgery was divided into two stages. The first stage, the tumor was excised by resecting the segment of mandible according to the preplanned radiograph. Twelve patients underwent resection of mandibular ameloblastoma or myxoma with 1 cm safe margin in the first surgery. Preoperative computed tomography (CT) scans were acquired, and CT data were imported into CMF software which guide the resection margins at operation. Patients were replaced with temporary Bowerman Conroyd appliance as space maintainer Figure 2.

Virtual planning and fabrication of model

Before the second surgery, the patients were sent for CT scan and the data were analyzed virtually using software

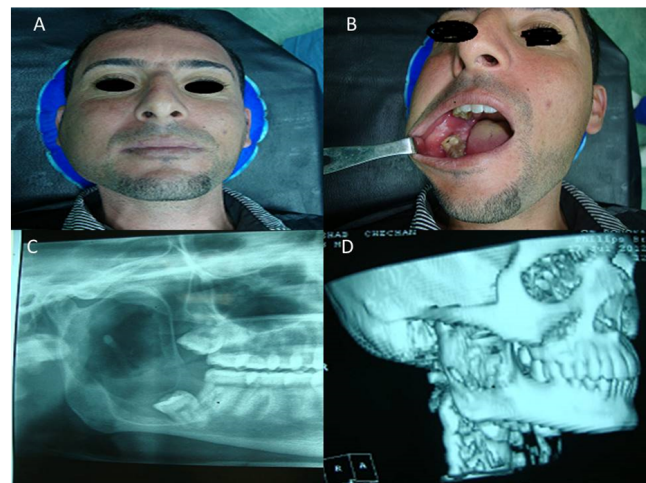

Figure 1. Ameloblastoma of the mandible. (A) Extra-oral and (B) Intraoral photograph of patient with ameloblastoma of the right mandible, (C) and (D) Showed right sided mandibular defect on Orthopantomogram (OPG) and Computed tomography (CT).

V 3.8.7. The simulation allowed construction of an individual mandibular model of zirconium material

A cone beam computed tomography CBCT was taken for the patient with CS 8100 3D (care stream health Inc, France) using CS 3D imaging software V 3.8.7, field of view was $8 \times 9 \text{ cm}^2$, KVP 90, mA5.0 exposure time 7 seconds and slice thickness 100m to get a 3D image in DICOM format. The DICOM then converted in to 3 D model using 3D in Vesalius software Ink 3.1.1 (Brazil) which is an open source medical program for 3D reconstruction as it uses a sequence of 2D dicom image acquire with CT scanner allowing exporting them in to 3D volume or surfaces as a mesh in STL format to create a physical model for patient .

Then we use a designing software Dental CAD DB Valletta 2.2 developed by (exocod GmbH Germany), it designs a reconstructive maxillofacial prosthesis depend upon a 3D model for patient anatomy with its defect. After prosthesis designing completion, it send to milling machine CAD-CAM Amangirrbach (Germany), then prosthesis milled with zirconia block and placed in a special furnace at 1450°C for two hour for sintering and hardening, then the prosthesis was packed for Autoclave sterilization to be ready at the time of surgical operation The holes are designed and constructed in the model to accommodate screws for fixation and placement of titanium implants in future. In the second reconstructive surgery, the space maintainer was removed and the defect was reconstructed by precisely designed zirconia appliance Figure 3 and 4.

Eight patients have mandibular defects due to previous trauma or developmental anomalies. These cases were reconstructed in single surgical procedure after construction of CT- designed model of zirconia material Figure 5. We also prepared holes in the prosthesis preoperatively to accommodate future dental implants. All the patients accept the cost (350 USD) of zirconium material.

The data were analyzed using Microsoft Excel 2010 and the results were presented in tables.

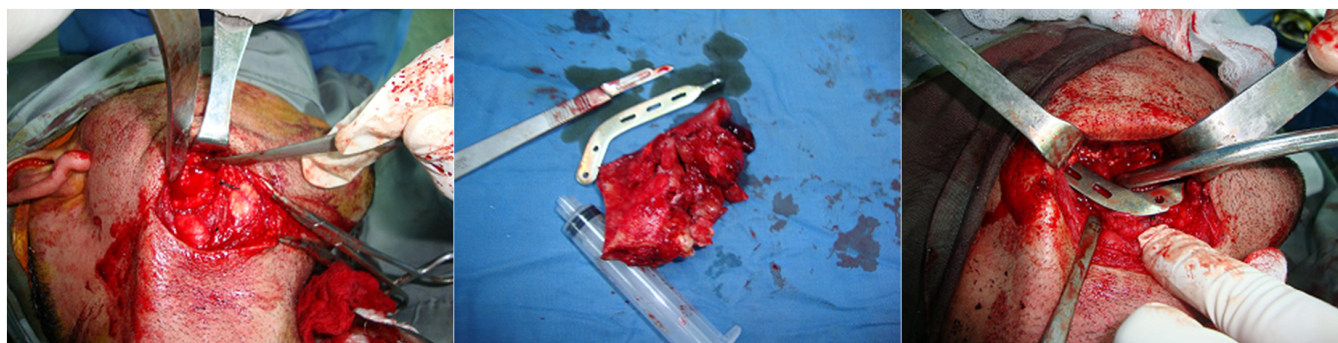

Figure 2. Resection of tumor and replacement with Bowerman Conroyd appliance.

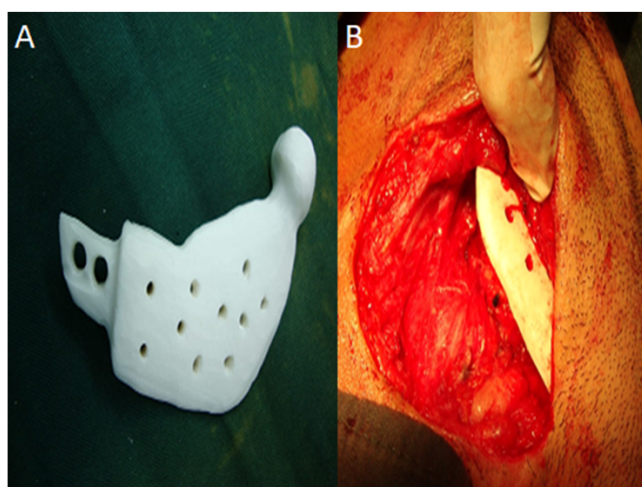


Figure 3. (A) Zirconia prosthesis. (B) Reconstruction of mandibular defect by zirconia prosthesis.

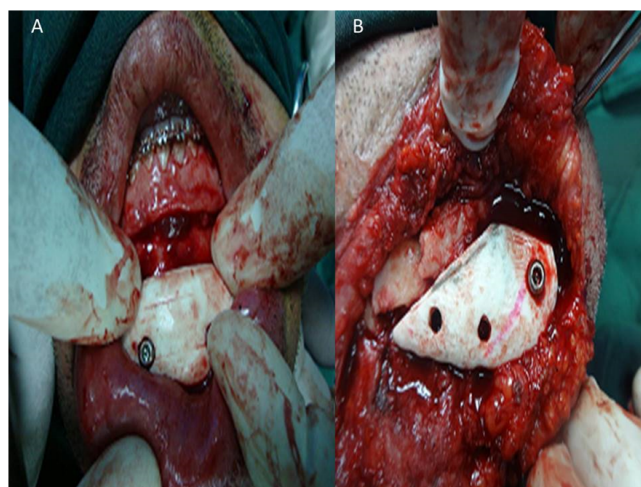


Figure 5. (A) Chin augmentation by zirconia prosthesis. (B) Augmentation of lower border of mandible with zirconia individual designed CAD/CAM prosthesis.

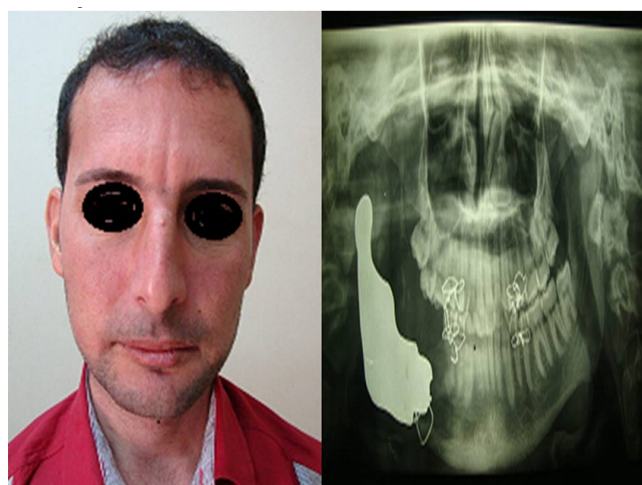

Figure 4. Photograph of one patient and OPG 1-year following surgery.

RESULTS

In the period between January 2012 and March 2017, 20 consecutive patients fit the inclusion criteria were included in

this study. The ratio of male to female in this study was 2.3 (14 male and 6 female). The aged ranged from 19-70 years with a mean age (39.45years \pm 3.7 SD).

The most common pathology in our study was ameloblastoma 10(50%), while, the least one myxoma 2(10%) Table 1. The most common site involved by all pathological types was mandibular body 12(60%), and the least condyle 3(15%) Table 1. The overall success rate of the reconstruction of the mandibular defects for all cases was 95%. Only one case of the 20 cases was failed due to infection with formation of fistula which necessitates removal of appliance Table 2. Also, the mandibular functions (mandibular occlusion, swallowing and etc..) were unaffected in remaining 19(95%) cases following the reconstruction.

The reconstructed mandible vertical height and facial contour and profile were improved, 25% of patients were good, and 70% adequate Table 3. No adverse reaction or rejection was observed to zirconia model. Some minor complications were encountered such as swelling and pain Table 4. The surgical time spent was 1 hour in the first surgery and 1 hour in the reconstructive surgery. The material remains intact successfully without any complications at the follow-up period 2.5–3 years. Out of 12 patients with mandibular body defects Table 1, only 7 patients they needed dental implants.

Table 1. Distribution of mandibular pathology/deformity according to its site.

Cause	Chin number	Condyle number	Mandibular body number	Total number
Tumors				
Ameloblastoma	2(10%)	1(5%)	7(35%)	10(50%)
Myxoma	1(5%)	0	1(5%)	2(10%)
Congenital	1(5%)	1(5%)	2(10%)	4(20%)
Traumatic	1(5%)	1(5%)	2(10%)	4(20%)
Total	5(25%)	3(15%)	12(60%)	20(100%)

Table 2. The clinical outcome of reconstruction of mandible by zirconia prosthesis with a follow-up period 2.5–3years.

Cause	Successful graft number	Failed graft number	Total number
Tumors			
Ameloblastoma	9(45%)	1(5%)	10(50%)
Myxoma	2(10%)	0	2(10%)
Congenital	4(20%)	0	4(20%)
Traumatic	4(20%)	0	4(20%)
Total	19(95%)	1(5%)	20(100%)

Table 3. Changes of facial contour postoperatively.

Facial contour	Number	Percentage
Good	5	25%
Adequate	14	70%
Poor	1	5%
Total	20	100%

Table 4. Postoperative complications of the mandibular reconstruction.

Complications	Number of patients	Percentage
Pain	20	100%
Edema	12	60%
Infection	1	5%
Dehiscence	1	5%
Prosthesis exposure or fracture	0	0%
Facial or midline asymmetry	2	10%
Trismus	2	10%

Unfortunately, they postponed the implants to an unknown time.

DISCUSSION

The mandible is an important part of facial skeleton which is required for facial esthetics, speech, mastication and respiration [14]. Mandibular defects may result from different causes such as congenital defect, inflammation, trauma and tumor. Reconstruction of the mandible is a challenging procedure, and various procedures are present, but these techniques have their associated pros and cons [15, 16]. Treatment depends on the surgeons training, patient preferences and available resources. These techniques include reconstruction plate

with or without pedicled myocutaneous flaps, alloplastic materials, free bone grafts, pedicled osteomyocutaneous flaps, and various free vascularized bone flaps [17]. However, autogenous free bone grafts have limitations and disadvantages including complications of the donor site, insufficient volume of bone, and undergoing resorption during the healing period [18]. While other types of bone grafts (allogeneic and xenogeneic bones) have the disadvantages of transmission of infection and possible immune reaction [18, 19].

Among the advantages of this technique were its simplicity and accuracy in comparison with vascularized bone reconstruction which requires complex procedure and teamwork. Reconstruction of the mandible using vascularized bone such as fibula is associated with donor site morbidity, and is often complicated by the advanced age of patient and coexisting conditions [20]. Alloplastic reconstruction using mandibular reconstruction plates may be followed by exposure or fracture of the plate, whereas not to reconstruct the defect results in poor functional and esthetic outcome. Confirmation of negative recurrence of tumor is important before reconstruction.

In this study there was superior functional and esthetic improvement for feeding, mouth competence and speech, minor complications, and mandibular symmetry in reconstruction of mandible defects. By this technique, the success rate of mandibular reconstruction with individual designed CAD/CAM zirconia model was 95%. Although there were previous attempts to use alloplastic materials in delay reconstruction of mandible like MedPor (high density porous polyethylene), Methylmetacrylate and silicone, these attempts were unsatisfactory and give unpredictable results [21, 22].

The facial contour was restored by zirconia model in the reconstructed patients. The contour and shape of mandible was restored well in cases who maintain the continuity of the mandible compared to those patients with a continuity defect. Ninety five percent of our subjects were satisfied about their facial contour. The failed case presented with orocutaneous fistula after reconstruction with zirconia model and the infection is not resolved with antibiotics and local measures. These results in agreement with the results obtained by many authors [15, 23]. The prior study by Hidalgo et al [23] reported on the esthetic outcome, in 75% of patients excellent to good, 15% fair and 10% poor.

Mandibular fixation devices such as reconstruction plate and Bowerman Conroyd appliance is very important in the first surgery. The mandibular fixation device was free and reusable. It can maintain the width of the mandible well, avoid mandibular ramus and condylar from slightly rotating or reversing in different directions, particularly in wide complex mandibular defects that lack a stable occlusion reference after tumor resection. Mandibular fixation devices can be bending into shape and contour of remaining mandible across the defect bypass the operative field, which will not affect the operation of the surgeon; the fixture design is reusable, which can be mass produced, making it cheap and easy to promote [24].

Why we choose zirconia? zirconia is one of the alloplastic bone grafts that shows excellent biocompatibility. Yttria-stabilized tetragonal zirconia polycrystals (Y-TZP) has excellent mechanical properties such as tensile and yield strength due to the fine grain size [25]. Y-TZP is a non-absorbable material and can be an excellent alloplastic graft material in facial skeleton. When compared to other alloplastic graft materials, zirconia expected to be a better block graft mate-

rial because it is easier to be manufactured, appropriate mechanical strength with porous structure, and any errors can be regulated during the processing [26]. No local (cellular) or systemic adverse reactions to the material were reported. Another important issue concerning the zirconia: we can replace the missed teeth in patients who need replacement by inserting zirconia dental implants in preoperatively prepared holes. Unfortunately, those (7) patient who needed dental replacement refused the dental implants at the time being.

The production of a block zirconia model that accurately fits a mandibular defect is possible by capturing and transforming the geometry of the defect to precise three-dimensional (3D) images using digital imaging systems, such as CAD/CAM system.

The CAD modeling software process the data and converts the actual bony defect into virtual model then the CAM technology transforms the data set into the desired model [27]. Recently, virtual surgical planning and computer-aided design (CAD)/computer-aided modeling (CAM) are attractive and well known methods in mandibular reconstruction and give opportunities for increased accuracy, improved efficiency, and enhanced outcomes [28].

CAD can be used to line osteotomy sites and measure the dimension of bone segments by simulating the operative process. Also before reconstruction, CAD can be used to provide

guidance for fabrication of accurate model for patient anatomical defect. Through model surgical techniques, CAD/CAM models, preoperative measured osteotomy guides, bite guides, pre-bent plates, and other models have greatly improved the accuracy of mandibular reconstruction surgeries [29].

The limitation of this study was the exclusion of malignant tumors of mandible and patients with radiotherapy. Minimal complications were reported after grafting of zirconia prosthesis such as mild pain, swelling. All of the patients (except one) in this study did not report major complication such as hematoma, infection and fracture of prosthesis.

CONCLUSION

We described a novel method for mandibular reconstruction with zirconium individual-designed CAD/CAM model. It combines zirconia block with CAD/CAM techniques and appropriate fixation which lead to improve the clinical outcomes (facial esthetic and mandibular functions). We advise to use this method for a large number of patients with different causes of mandibular defects in the future studies.

CONFLICT OF INTEREST

The author declare that there is no conflict of interest.

REFERENCES

- [1] M. Rashid, M. Zia ul Islam, and A. M. Bhatti. The 'expansile' supraclavicular artery flap for release of post-burn neck contractures. *J. Plast. Reconstr. Aesthetic Surg.*, 59(10):1094–1101, 2006.
- [2] A. Kalantar-Hormozi and B. Khorvash. Repair of skin covering osteoradionecrosis of the mandible with the fasciocutaneous supraclavicular artery island flap: case report. *J. Cranio-Maxillofacial Surg.*, 34(7):440–442, 2006.
- [3] C. L. Ortiz, A. V. Carrasco, A. N. Torres, L. N. Sempere, and M. M. Mendoza. Supraclavicular bilobed fasciocutaneous flap for postburn cervical contractures. *Burns*, 33(6):770–775, 2007.
- [4] R. D. Foster, J. P. Anthony, A. Sharma, and M. A. Pogrel. Vascularized bone flaps versus nonvascularized bone grafts for mandibular reconstruction: an outcome analysis of primary bony union and endosseous implant success. *Head Neck J. Sci. Spec. Head Neck*, 21(1):66–71, 1999.
- [5] P.-Y. Lin, K. C. Lin, and S.-F. Jeng. Oromandibular reconstruction: the history, operative options and strategies, and our experience. *ISRN Surg.*, 2011, 2011.
- [6] E. Genden and B. H. Haughey. Mandibular reconstruction by vascularized free tissue transfer. *Am. J. Otolaryngol*, 17(4):219–227, 1996.
- [7] M. L. Urken et al. Oromandibular reconstruction using microvascular composite flaps: report of 210 cases. *Arch. Otolaryngol. neck Surg.*, 124(1):46–55, 1998.
- [8] K. K. Yim and F. Wei. Fibula osteoseptocutaneous flap for mandible reconstruction. *Microsurgery*, 15(4):245–249, 1994.
- [9] B. H. Haughey, J. M. Fredrickson, A. J. Lerrick, A. Sclaroff, and W. D. Gay. Fibular and iliac crest osteomuscular free flap reconstruction of the oral cavity. *Laryngoscope*, 104(11):1305–1313, 1994.
- [10] H. Tideman and S. Lee. The tl endoprosthesis for mandibular reconstructiona metallic yet biological approach. *Asian J Oral Maxfac Surg*, 18(5), 2006.
- [11] K. Sevin, I. Askar, A. Saray, and E. Yormuk. Exposure of high-density porous polyethylene (medpor) used for contour restoration and treatment. *Br. J. Oral Maxillofac. Surg.*, 38(1):44–49, 2000.
- [12] S. Pilathadka, D. Vahalová, and T. Vosáhlo. The zirconia: a new dental ceramic material. an overview. *Prague Med Rep*, 108(1):5–12, 2007.
- [13] M. Pinheiro and J. L. Alves. The feasibility of a custom-made endoprosthesis in mandibular reconstruction: implant design and finite element analysis. *J. Cranio-Maxillofacial Surg.*, 43(10):2116–2128, 2015.
- [14] B. Spiessl. Internal fixation of the mandible: a manual of ao/asif principles. *Springer Science and Business Media*, 2012.
- [15] P. G. Cordeiro, J. J. Disa, D. A. Hidalgo, and Q. Y. Hu. Reconstruction of the mandible with osseous free flaps: a 10-year experience with 150 consecutive patients. *Plast. Reconstr. Surg.*, 104(5):1314–1320, 1999.
- [16] D. A. Hidalgo. Fibula free flap: a new method of mandible reconstruction. *Plast. Reconstr. Surg.*, 84(1):71–79, 1989.
- [17] B. P. Kumar, V. Venkatesh, K. A. J. Kumar, B. Y. Yadav, and S. R. Mohan. Mandibular reconstruction: overview. *J. Maxillofac. Oral Surg.*, 15(4):425–441, 2016.
- [18] D. L. Hoexter. Bone regeneration graft materials. *J. Oral Implantol.*, 28(6):290–294, 2002.
- [19] J. B. Quattlebaunr, J. T. Mellonig, and N. F. Hensel. Antigenicity of freeze-dried cortical bone allograft in human periodontal osseous defects. *J. Periodontol.*,

- 59(6):394–397, 1988.
- [20] I. Moldovan et al. Mandibular reconstruction using free vascularized iliac crest grafts and dental implants. *Chujul Med.*, 88(3):391, 2015.
 - [21] P. Sadr-Eshkevari, A. Rashad, S. A. Vahdati, A. Gara-jei, B. Bohluli, and P. Maurer. Alloplastic mandibular reconstruction: a systematic review and meta-analysis of the current century case series. *Plast. Reconstr. Surg.*, 132(3):413e–427e, 2013.
 - [22] L. Gui, L. Huang, and Z. Zhang. Genioplasty and chin augmentation with medpore implants: a report of 650 cases. *Aesthetic Plast. Surg.*, 132(2):220–226, 2008.
 - [23] D. A. Hidalgo, A. L. Pusic, and F.-C. Wei. Free-flap mandibular reconstruction: a 10-year follow-up study. *Plast. Reconstr. Surg.*, 110(2):438–449, 2002.
 - [24] M. Y. Jia, J. J. Jiang, X. Y. Chu, R. T. Yuan, K. Wang, and L. X. Bu. Clinical application of titanium plate reconstruction of mandibular defect: 10 years of follow up. *Chinese J. Stomatol.*, 51(7):401–404, 2016.
 - [25] H. J. Wenz, J. Bartsch, S. Wolfart, and M. Kern. Os-seointegration and clinical success of zirconia dental implants: a systematic review. *Int. J. Prosthodont.*, 21(1), 2008.
 - [26] I.-J. Kim and S.-Y. Shin. Comparative study of new bone formation capability of zirconia bone graft material in rabbit calvarial. *J. Adv. Prosthodont.*, 10(3):167–176, 2018.
 - [27] H. Shao et al. Custom repair of mandibular bone defects with 3d printed bioceramic scaffolds. *J. Dent. Res.*, 97(1):78–76, 2018.
 - [28] A. Tarsitano et al. Accuracy of cad/cam mandibular reconstruction: A three-dimensional, fully virtual outcome evaluation method. *J. Cranio-Maxillofacial Surg.*, 46(7):1121–1125, 2018.
 - [29] B. D. Foley, W. P. Thayer, A. Honeybrook, S. McKenna, and S. Press. Mandibular reconstruction using computer-aided design and computer-aided manufacturing: an analysis of surgical results. *J. Oral Maxillofac. Surg.*, 71(2):e111–e119, 2013.