

Non-Hodgkin's Lymphoma: a Preliminary Morphometric Study

Aiad Abdullah Abdulrazak

Department of Pathology, Tikrit College of Medicine, University of Tikrit, Iraq

Abstract

Background: Assessment of nuclear morphology is crucial for the diagnosis of non-Hodgkin's lymphoma. However, it is often hampered by subjectivity and inter-observer variation.

Objectives: This work is aimed at studying the usefulness of nuclear morphometry as an objective approach to the diagnosis of non-Hodgkin's lymphoma.

Material and Methods: Hematoxylin-Eosin stained sections from twenty-eight cases of non-Hodgkin's lymphoma was evaluated for nuclear size, area and perimeter by semi-automated image analysis system.

Results: The parameters related to nuclear morphology (nuclear size, area, & perimeter) of neoplastic lymphocytes were significantly higher in large cell lymphoma as compared to small cell, intermediate cell & Burkitt's lymphoma but, not for mixed cell lymphoma. This finding was further substantiated when calculating the overlap index.

Conclusion: This study supports the assumption that nuclear morphometry offers a more objective and reproducible diagnostic method for subcategorizing lymphoid tumors than is currently possible by conventional histopathological techniques.

Corresponding author: Aiad Abdullah Abdulrazak, aiadalkhalidi@gmail.com

Introduction

The diversity of classification systems for non-Hodgkin's lymphomas (NHL) reflects the difficulty encountered by most histopathologists in defining the histological diagnosis of lymphoid tumors accurately and reproducibly^{1,2}.

Morphologically, lymphoma cells can be classified by their size as small, medium, or large cells using the nuclear size of the endothelial cells of small vessels and benign histiocytes as an internal control³. Because of differences in natural history, patient presentation, response to treatment, and prognosis as well as the implications for clinical trials, it is important to make an accurate typing of NHL. Hence any attempt to improve typing accuracy and provide sufficient discrimination to supplant more conventional morphological assessments by light microscopy is welcomed.

Apart from conventional routine of hematoxylin & eosin stained sections, lymphoid tumors had been studied ultrastructurally and immunohistochemically in attempt to refine lymphoma classification. An alternative approach, as yet little explored, concerns the use of image analyzers for quantitative morphometrical analysis of lymphoma cells. This possibility has been studied by Crocker and Curran using a Zeiss Microvideomat to measure the mean nuclear diameter of cells in imprints from lymphoid tumors and reactive lymph nodes. Some discrimination was obtained between these conditions; however, the television-based image analyzers provided poor definition of closely adjacent cells precluding its use for tissue sections⁴.

This study is a preliminary evaluation of a computerized morphometric analysis of paraffin-embedded lymph node sections of non-Hodgkin's lymphomas as an

accurate and objective diagnostic tool for lymphoid tumors.

Materials and Methods

Case selection

Twenty-Eight cases of non-Hodgkin's lymphoma were studied retrospectively. The studied cases were classified according to the modified Working formulation system (Table 1)^{5,6}.

This study includes nine cases of Diffuse Large cell lymphoma (LCL), eleven cases of small cell lymphoma (SCL), four cases

of intermediate lymphocytic/Mantle cell lymphoma (ICL), two cases of Burkitt's lymphoma (BL) and two cases of mixed large and small cell lymphoma (MCL). For each case, Hematoxylin & Eosin stained histological sections were examined by at least two pathologist who agreed the final diagnosis. Sections were randomly selected from archived slides of Basrah teaching hospital (1985-1999) & the slide museum of the pathology department, Tikrit college of Medicine.

Table 1. The Working Formulation of Non-Hodgkin's Lymphomas for Clinical Use.

Low-grade

- Small lymphocytic lymphoma; includes chronic lymphocytic leukemia & plasmacytoid lymphocytic lymphoma.
- Follicular, small, cleaved cell lymphoma.
- Follicular, mixed small cleaved and large cell lymphoma.
- Intermediate or mantle zone lymphoma.[§]
- Monocytoid B cell lymphoma.[§]

Intermediate-grade

- Follicular, large cell lymphoma.
- Diffuse small cleaved cell lymphoma.
- Diffuse, mixed small and large cell lymphoma.
- Diffuse, large cell (cleaved and noncleaved) lymphoma.

High-grade

- Large cell, immunoblastic lymphoma.
- Lymphoblastic (convoluted and nonconvoluted cell) lymphoma.
- Small noncleaved cell (Burkitt's) lymphoma.
- Anaplastic large cell lymphoma.

Miscellaneous

Composite, mycosis fungoides, histiocytic lymphoma; extramedullary plasmacytoma, unclassifiable, others.

[§] **Not part of original formulation.**

Morphometric analysis

Well-stained microscopic fields at magnification x400 were randomly selected and captured for each case using a Benq® digital camera. An average of 40

nuclei of tumor cells was analyzed per slide.

Care was taken to include only intact whole nuclei from the actual lesion, avoiding the nuclei of stromal cells.

Overlapped and fragmented nuclei were discarded. The morphometric analysis was

done using the Windows® based image analysis software (imagej 1.43 from the institute of health, USA) and Digimizer® version 3.7.1.0 software) as previously described^{7,8}. Measurements were calibrated in terms of micrometer, using a calibrated eyepiece graticule before each measurement (Figure 1).

Nuclear area and perimeter were measured directly by the image analysis software, while the nuclear size was computed using the formula $[2 \times (\text{nuclear area}/\pi)^{0.5}]$

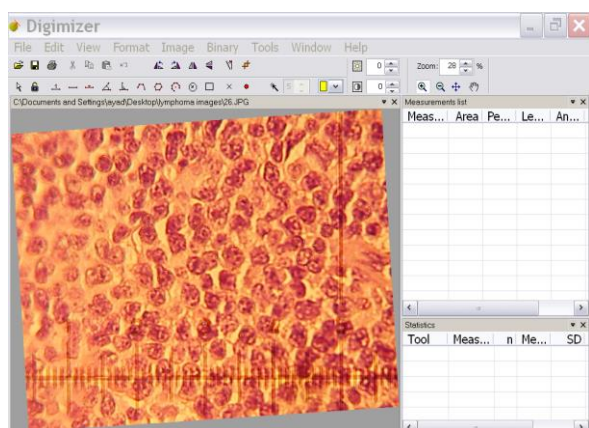


Figure 1: microphotograph of diffuse large cell lymphoma, including the calibration scale & projected by the image analytic software for nuclear evaluation.

Statistical analysis

Data were statistically analyzed by Medcalc® software and SSP (Smith statistical package) briefly:

1- To assess the significance of our observations, the mean of morphometric measurements were compared using the Mann-Whitney nonparametric test, one way ANOVA, and the unpaired t-test.

2- The overlap index (OI), a nonparametric, mathematically derived index useful for quantifying the degree of overlap between two sets of data. As applied to NHL, OI help to evaluate which nuclear feature best distinguishes between the various subtypes. The value for the overlap index will be zero if there is no overlap between two sets of observations and one if both samples have the same median.⁹

3- Reproducibility: In order to test reproducibility, measurements of nuclear features were repeated twice in five randomly selected cases, the mean values of re-test measurements were compared to the mean values of initial measurements using independent student's *t*-test.

Results

1- Mean Nuclear Parameters

The mean values derived from pooled data for lymphocytes nuclear area, perimeter and nuclear size in each of the subtypes of non-Hodgkin's lymphoma are presented in Table 2. The mean values and the range of measurements are illustrated in Figure 2 (nuclear area), Figure 3 (nuclear perimeter) and Figure 4 (nuclear size).

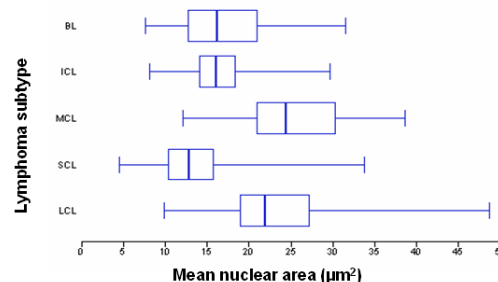


Figure 2: Mean Nuclear area (µm²) of neoplastic lymphocytes according to lymphoma subtypes LCL (large cell NHL), SCL (Small Cell NHL), ICL (intermediate cell NHL), MCL (Mixed large & Small cell NHL), BL (Burkitt's Lymphoma)

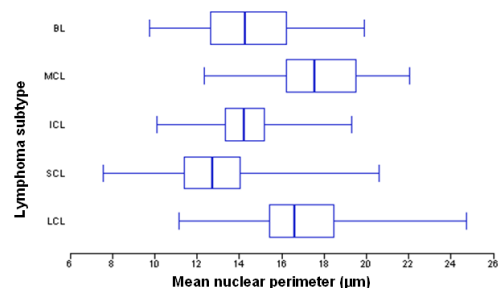


Figure 3: Mean Nuclear perimeter (µm) of neoplastic lymphocytes according to lymphoma subtypes LCL (large cell NHL), SCL (Small Cell NHL), ICL (intermediate cell NHL), MCL (Mixed large & small cell NHL), BL (Burkitt's lymphoma)

Non-Hodgkin's Lymphoma ...

Aiad A. Abdulrazak

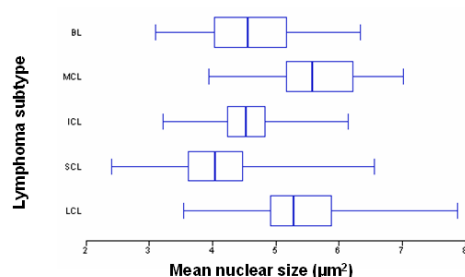


Figure 4: Mean Nuclear size (μm^2) of neoplastic lymphocytes according to lymphoma subtypes LCL (large cell NHL), SCL (Small Cell NHL), ICL (intermediate cell NHL), MCL (Mixed large & small cell NHL), BL (Burkitt's lymphoma).

The mean nuclear area of neoplastic lymphocytes was significantly larger in large cell lymphoma (23.35 ± 6.47) as compared to small cell lymphoma (13.45 ± 6.47); intermediate cell lymphoma (16.22 ± 3.29) and Burkitt's lymphoma (17.17 ± 5.04).

Neoplastic lymphocytes of large cell lymphoma have a significantly higher nuclear perimeter (16.93 ± 2.33) as compared to the mean nuclear perimeter of small cell lymphoma (12.83 ± 2.1); intermediate cell lymphoma (14.29 ± 1.47) and Burkitt's lymphoma (14.53 ± 2.15).

Table 2: Pooled Morphometric Data for Nuclear Parameters

Lymphoma subtype [#]	Area (μm^2)	Perimeter (μm)	Nuclear size
LCL mean \pm SD (N ^{\$} =388)	23.25 \pm 6.47	16.93 \pm 2.33	5.4 \pm 0.74
SCL mean \pm SD (N =401)	13.45 \pm 4.56	12.83 \pm 2.1	4.08 \pm 0.67
MCL mean \pm SD (N =64)	25.37 \pm 6.63	17.71 \pm 2.26	5.64 \pm 0.72
ICL mean \pm SD (N = 172)	16.22 \pm 3.29	14.29 \pm 1.47	4.55 \pm 0.46
BL mean \pm SD (N =99)	17.17 \pm 5.04	14.53 \pm 2.15	4.63 \pm 0.68
p- value*	LCL vs SCL LCL vs ICL LCL vs BL SCL vs MCL SCL vs ICL SCL vs BL BL vs MCL ICL vs MCL ICL vs BL: LCL vs MCL:	LCL vs SCL LCL vs ICL LCL vs BL SCL vs MCL SCL vs ICL SCL vs BL BL vs MCL ICL vs MCL ICL vs BL: LCL vs MCL:	LCL vs SCL LCL vs ICL LCL vs BL SCL vs MCL SCL vs ICL SCL vs BL BL vs MCL ICL vs MCL ICL vs BL: LCL vs MCL:

Lymphoma subtypes: LCL (large cell NHL), SCL (small cell NHL), ICL (intermediate cell NHL), MCL (mixed large & small cell NHL), BL (Burkitt's lymphoma)

\$ N: refers to number of measured nuclei.

* Mann-Whitney test

Table 3: Indices of overlap between lymphoma subtypes*

	SCL vs LCL	SCL vs ICL	MCL vs ICL	LCL vs ICL	LCL vs MCL	LCL vs MCL
Nuclear area	0.18	0.11	0.21	0.32	0.81	0.81
Nuclear perimeter	0.24	0.89	0.23	0.33	0.79	0.79
Nuclear size	0.18	0.22	0.22	0.32	0.79	0.79

* Lymphoma subtypes : *LCL* (large cell NHL), *SCL* (small cell NHL), *ICL* (intermediate cell NHL), *MCL* (mixed large & small cell NHL),

The mean nuclear size was found to be significantly higher in large cell lymphoma (5.4 ± 0.74) than for small cell lymphoma (4.08 ± 0.67); intermediate cell lymphoma (4.55 ± 0.46) and Burkitt's lymphoma (4.63 ± 0.68).

2- Overlap index

This mathematical score is useful for comparing the degree of overlap between two sets of observations. Thus, in Table 3, overlap indices almost approaching zero indicate relatively distinctive subtypes of non-Hodgkin's lymphoma (Large cell lymphoma versus small cell and intermediate cell lymphomas) and (intermediate cell lymphoma versus small cell and mixed cell lymphoma).

However, there is considerable overlap between large cell and mixed-large cell & small cell lymphoma (MCL), i.e., overlap index approaching one.

3- Reproducibility: eatability

Reproducibility was tested by duplicate measurements in five randomly selected cases (three large cell lymphoma and two small cell lymphoma). The mean values of nuclear area, perimeter and size of the initial and re-test measurements were compared using student's t-test and the difference was statistically insignificant.

Discussion

The gold standard in the diagnosis of non-Hodgkin's lymphoma (NHL) is the microscopic examination of tumor tissue samples. The appearance and size of nuclei are of prime diagnostic importance. However, subjective (qualitative) assessment of nuclear features is tedious and prone to considerable inter- and intra-observer variation³.

The results of cellular morphometric study can be affected by the fixation solution, fixation time, cutting thickness of the tissue, and staining solution. In our study, the traditional routine tissue processing was adopted, including 10% neutral formalin fixation, paraffin embedding, 4- μ m section thickness, and hematoxylin-eosin staining, to obtain relatively representative results^{10,11}.

Image-analyzer machines (such as Zeiss microvideomat) had been attempted to obtain more objective and reproducible assessment of nuclear features. However, aside from being costly and even with sections cut at conventional thickness, there is considerable overlap or contact between cells or nuclei. Thus cell clusters are "read" by the machine as a single, large object and the end result may be inaccurate¹².

Non-Hodgkin's Lymphoma ...

Aiad A. Abdulrazak

Our results show that it is feasible to undertake morphometric analysis of tissue sections from lymphoid tumors with specialized image analysis software's. In four out of five lymphoma subtypes it was possible to separate tumors by nuclear size, area and perimeter with good correlation with initial histopathological sub-typing by light microscopy.

The mean nuclear area of neoplastic lymphocytes was significantly larger in large cell lymphoma (23.35 ± 6.47) as compared to small cell lymphoma (13.45 ± 6.47); intermediate cell lymphoma (16.22 ± 3.29) and Burkitt's lymphoma (17.17 ± 5.04).

Neoplastic lymphocytes of large cell lymphoma have a significantly higher nuclear perimeter (16.93 ± 2.33) as compared to the mean nuclear perimeter of small cell lymphoma (12.83 ± 2.1); intermediate cell lymphoma (14.29 ± 1.47) and Burkitt's lymphoma (14.53 ± 2.15).

The mean nuclear size was found to be significantly higher in large cell lymphoma (5.4 ± 0.74) than for small cell lymphoma (4.08 ± 0.67); intermediate cell lymphoma (4.55 ± 0.46) and Burkitt's lymphoma (4.63 ± 0.68).

Our findings agreed with Abbott et al who reported that the nuclear area correlates with the histopathological subtype of NHL¹³. In contrast to our findings, Crocker and Curran were unable to relate the mean diameter of neoplastic lymphoid cells to specific subtypes of NHL in spite of that their studies were conducted with imprints of unfixed lymph nodes (expectantly provide less crowded non-overlapped cell population) whereas we employed fixed and processed tissues and this discrepancy between our findings may partly related to the problem of defining nuclear boundaries in images processed by the television-based image analyzer (Zeiss Microvideomat)⁴.

Based on the observations of current study, it was not possible to morphometrically separate large cell lymphoma (LCL) from mixed large cell and small cell lymphoma (MCL). This is probably reflects misdiagnosis of some cases of LCL as a MCL or that large cells outnumber small cells in these tumors.

Similar problem had been encountered by Abbott and Coworkers¹³ who performed morphometry by automated image-analyzers Quantimet 720 and Kontron MOP/AMO₃.

The overlap index (OI) was calculated for all nuclear parameters to quantify the degree of morphometric overlap among lymphoma subtypes and to identify those parameters which permit clear-cut distinctive sub-typing of lymphoid tumors.

We found that overlap indices almost approaching zero when comparing (large cell lymphoma versus small cell and intermediate cell lymphomas) and (intermediate cell lymphoma versus small cell and mixed cell lymphoma).

However, there is considerable overlap between large cell and mixed-large cell and small cell lymphoma (MCL), i.e, overlap index approaching one.

Although we succeed in subtyping of NHL based on nuclear morphometry, none of the assessed nuclear parameters allow clear-cut distinction of all five lymphoma subtypes, precluding an immediate diagnostic application for the technique. Apparantly, other nuclear characteristics such as chromatin pattern, nucleolar size and number and nuclear contour and cleavage need to be studied hopefully they provide better distinction among lymphoid tumors.

In conclusion, our study supports the assumption that nuclear morphometry offers a more objective and reproducible diagnostic method for subcategorizing lymphoid tumors than is currently possible by conventional histopathological techniques.

References

- 1- Horning S. J. Something old, something few, something subjective, *J of Clinical Oncology*. 2003, 21(1); 1-2.
- 2- A. E. Martinez, et al. grading of follicular lymphoma: Comparison of routine histology. *Arch of Pathol. 2007, Lab Med.*, 131(7).
- 3- Jaffe ES, Harris ML, Stein H, Isaacson PG- Classification of lymphoid neoplasms: the microscope as a tool for disease discovery. *Blood*, 2008, 312:4384-99.
- 4- Crocker J, Curran RC. A study of nuclear diameters in lymph node imprints using the Zeiss Microvideomat. *J Clin Pathol.* 1979, 32:670-4.
- 5- The lymphoid system: II. Malignant Lymphomas, In: Chandrasoma P, Taylor CR: Concise Pathology, 3rd ed., McGraw-Hill, P 449.
- 6- Shivdasani RA, Hess JL, Skarin AT, and Pinkus GS: Intermediate lymphocytic lymphoma: clinical and pathologic features of a recently characterized subtype of non-Hodgkin's lymphoma. *J Clin Oncol.* 1993 Apr; 11(4):802-111.
- 7- Aiad HA, Abdou AG, Bashandy MA et al: Computerized nuclear morphometry in the diagnosis of thyroid lesions with predominant follicular pattern. *Ecancer*, 2009, 3:149,
- 8- lu-Han Lee, Eun Mee Han, Zhen-Hua Lin, et al: Clinicopathologic Significance of Nuclear Grooves and Inclusions in Renal Cell Carcinoma. *Arch Pathol Lab Med.* 2008, 132:940.
- 9- Dardick I, Douglas CR: Follicular Center Cell Lymphoma: Morphologic Data Relating to Observer Reproducibility. *Cancer* 1986, 58:2477-2484.
- 10- Baek T, Huh J, Kwak H: Image analytic study of nuclear area in mantle cell lymphoma. *Korean J Hematol.* 2010, 45:193-6.
- 11- Ondracek RP, Parker F, Allen A, et al. Standardization of nuclear morphometry based biomarkers. *Anal Quant Cytol Histol*, 2007, 29:309-16.
12. Crocker J: Morphometric and related quantitative techniques in the study of lymphoid neoplasms. A review. *J pathol.* 1984, 143:69-80.
13. Abbott Cr, Blewitt Rw, C Bird CC: Quantitative analysis of non-Hodgkin's lymphoma. *J Clin Pathol.* 1982, 35:135-138.