

# Rare Sites of the Hydatid Cyst

Mohammed Tafash Dagash

FICMS – CTVS , Instructor , Department of Surgery Al-Anbar Medical College.

## Abstract:

**Background:** Cystic hydatidosis caused by *Echinococcus granulosus* is an important zoonotic world wide. Although all the sites of the body can be a possible location of the parasite , skin is an example of an uncommon site.

**Objective :** To determine the hydatid cyst which can occur any where in human body even the skin , & can deal with it first due to can do this operation under local anesthesia or possibility of rupture .

**Materials& Methods:** prospective study of five patients present with skin swelling . The diagnoses were made in three cases by incidental finding during operation for exploration of the skin swelling for diagnostic & therapeutic . The remaining two cases diagnosis is preoperative by high suspension .

**Results:** out of five patients aged between 30-70 years with skin swelling (average 50 years ) , three of them incidental discover preoperative with 60 % female & 40 % male .

**Conclusion & Recommendation :** Two of them are as secondary hydatid cyst & other three are primary hydatid cyst . Although it is rare hydatid cyst of skin , it should be considered in the differential diagnosis of skin swelling ,especially in endemic areas.

---

**Key words :** Hydatid cyst , Skin , Iraq .

## Introduction :

Hydatidosis caused by *Echinococcus granulosus* is one of the most important zoonotic disease. The four species known to

infect man are *E.granulosus*,*E.multiloculosus*, *E.oligathrus* , & *E.vogeli*.<sup>1</sup> Life cycle of the parasite :

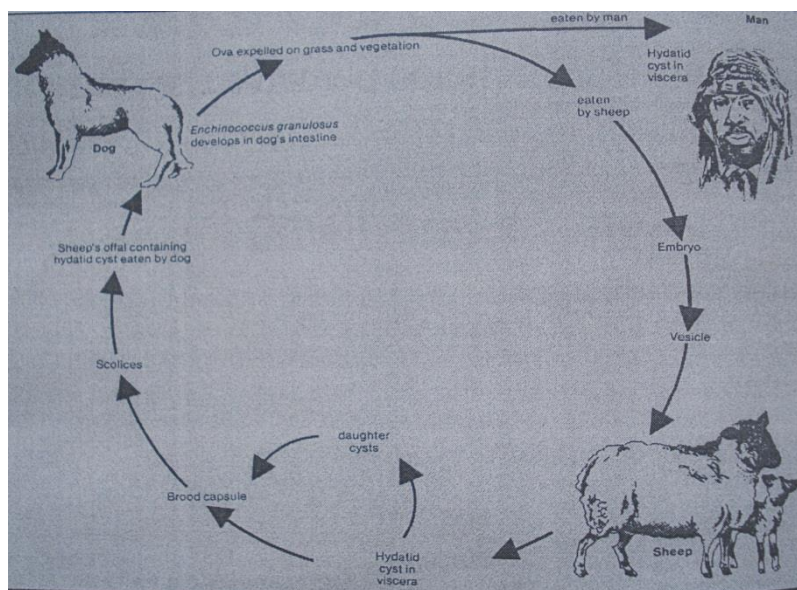


Fig. 1 Life cycle of the parasite <sup>2</sup>

Hydatid disease is caused by the adult & larval stages of *Echinococcus granulosus*. The adult is a cestode of 5 to 7 mm in length with a scolex bearing four suckers & with a body containing two to six proglottids. The larval stage or metacestode is a cyst with an acellular laminated outer layer & an inner nucleated germinal layer which gives rise to brood capsules & then scolices. The adult worm lives in dog which is the primary host. The cystic part of the cycle occurs in sheep, ox, pig, horse, camel or man, which act as intermediate hosts.

The adult worm lives in the dog's intestine for months. The terminal segment proglottids detach from the worm & release thousands of ova with the stools.

These are ovoid in shape & can remain infective for long periods. Ingestion of the ova by sheep in contaminated water, grass or vegetables causes infection, & hydatid cysts subsequently develop in the viscera. The parasite gets back into the dog when the sheep is slaughtered & its viscera containing cysts are eaten by another dog. In each of these cysts thousands of scolices are found which will grow into new tape worms in the dog's intestine & so the cycle repeats itself indefinitely.

If an ovum gets into a man instead of a sheep, the life cycle of the parasite will be broken, because the entrails of men are not eaten by dogs.

Contamination of food is a common source of infection in man, more frequently he contaminates his fingers by fondling a dog & then takes his food without washing his hands. The ova hatch in the stomach & the hexacanth embryos or oncospheres are released in the stomach & duodenum & pass through the wall & travel via portal vein to the liver, where the majority settle & develop into hydatid cysts.

Only those embryos which successfully pass through the capillaries in the liver to reach the lungs develop into hydatid cysts, & few which get through the lungs are then carried to the viscera & tissues supplied by the systemic circulation.

Sometimes the hatched embryo passes through the wall of the stomach or the duodenum into a lymphatic channel to be carried to the lungs via thoracic duct, thus bypassing the liver, this explains the few cases of pulmonary hydatids without hepatic involvement. Once implanted in the interstitial tissue of the lung, the embryo grows into a vesicle & then into a hydatid cyst.<sup>3</sup>

The hydatid cyst is surrounded by a capsule, its adventitia (pericyst) is part of the host, the hydatid cyst itself is composed of a nucleated thin germinal layer (endocyst) which secretes the hydatid fluid into its cavity & forms externally an acellular white laminated membrane (ectocyst).<sup>3</sup>

A primary hydatid cyst indicates that the cyst has developed from an ovum, whilst secondary hydatid cyst means that a primary cyst lodged in the lung, liver or other site of the body has ruptured & caused new daughter cysts to develop.<sup>3</sup>

### **Materials & methods:**

This is a descriptive & prospective study was done on 5 patients operated in Al-Falluja General Hospital in the period of July 2007- July 2008.

The collected data included age, gender, date of admission, duration of swelling, history of contact with dogs & endemic areas from the patients or from their relatives.

Three cases from the periphery of city & other from center of city with history of traveling to rural area during the 3<sup>rd</sup> Gulf war.

The diagnosis was made in different ways , group of patients ( 3 cases ) incidentally discover during operative exploration of the skin swelling for diagnostic & therapeutic .

Another group of patients ( 2 cases ) diagnosed preliminary by history of a know case of hydatid cyst ,radiographic for chest , localize site ( upper third of left leg hydatid cyst involving tibia & fibula) & ultrasonography .

Cystectomy was performed under local anesthesia in 2 patients & 3 patients under general anesthesia .

The tissue & cyst obtained after operation subjected to histopathological study in 4 cases reveally hydatid cyst , other case by macroscopical appearance ( case no.1) & latter on by right thoracotomy for lung hydatid cyst.

### **Results:**

Age , gender,complain,duration,local sign, type of anesthesia,diagnosis,other organ involvement, type of hydatid cyst & histopathological study distribution will be shown in table 1,2 & 3 respectively.

<b>Case no.</b>	<b>Age/ year</b>	<b>Gender</b>
<b>1.</b>	<b>30 y.</b>	<b>Female</b>
<b>2.</b>	<b>39 y.</b>	<b>Male</b>
<b>3.</b>	<b>70 y.</b>	<b>Female</b>
<b>4.</b>	<b>35 y.</b>	<b>Male</b>
<b>5.</b>	<b>55 y.</b>	<b>Female</b>

**Table 1 : Distribution of cases according the age & gender.**

<b>Case no.</b>	<b>Complain/ duration</b>	<b>Local sign</b>	<b>Other organ involve (liver &amp; lung)</b>
<b>1</b>	<b>Double cystic swelling on right shoulder/ 1 year</b>	<b>Round mobile not pulsatile mass</b>	<b>Liver &amp; lung involve (ultrasound &amp; chest x-ray)</b>
<b>2</b>	<b>Single cystic mass on the back/ 1 year</b>	<b>Fluctuant ,painless, with skin vascular change</b>	<b>Not involve</b>
<b>3</b>	<b>Single left supraclavicular mass / 5 year</b>	<b>Mobile cystic mass, not pulsatile</b>	<b>Not involve</b>
<b>4</b>	<b>Cystic lesion at the site of previous thoracotomy incision / 1 year</b>	<b>Mobile, cystic mass, scar of thoracotomy before 10 year</b>	<b>Right lung &amp; posterior mediastinum</b>
<b>5</b>	<b>Recurrent cystic lesion on left upper 3<sup>rd</sup> of leg just below knee/ 2 year</b>	<b>Mobile cystic mass</b>	<b>Not involve</b>

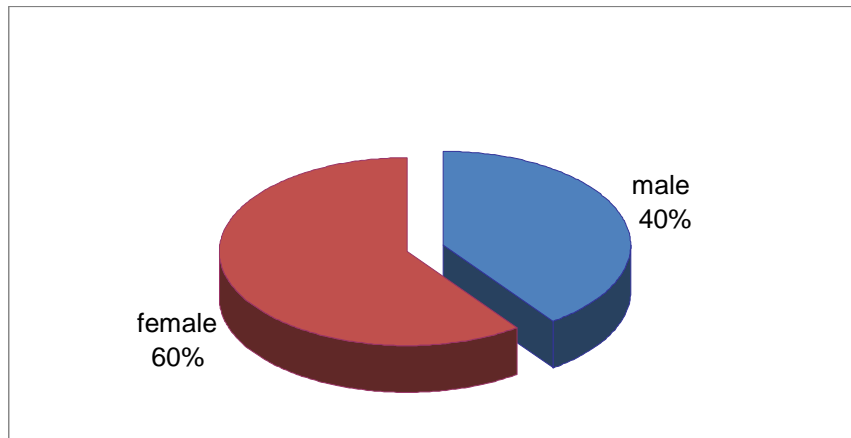
Table 2 : distribution of cases according complain ,duration ,local sign & other organ involvement.

<b>Case no.</b>	<b>Type of anesthesia</b>	<b>Diagnosis</b>	<b>Type of hydatid cyst</b>	<b>Histopatholog</b>
<b>1</b>	<b>Local</b>	<b>incidental</b>	<b>primary</b>	<b>Macroscopical features of H.cyst</b>
<b>2</b>	<b>Local</b>	<b>incidental</b>	<b>primary</b>	<b>Macroscopical &amp; microscopical</b>
<b>3</b>	<b>General</b>	<b>incidental</b>	<b>primary</b>	<b>Macroscopical &amp; microscopical</b>
<b>4</b>	<b>General</b>	<b>High suspension with history of lung Hydatid cyst</b>	<b>secondary</b>	<b>Macroscopical &amp; microscopical</b>

5	General	High suspension with a known case in the same site	secondary	Macroscopical & microscopical
---	---------	--	-----------	-------------------------------

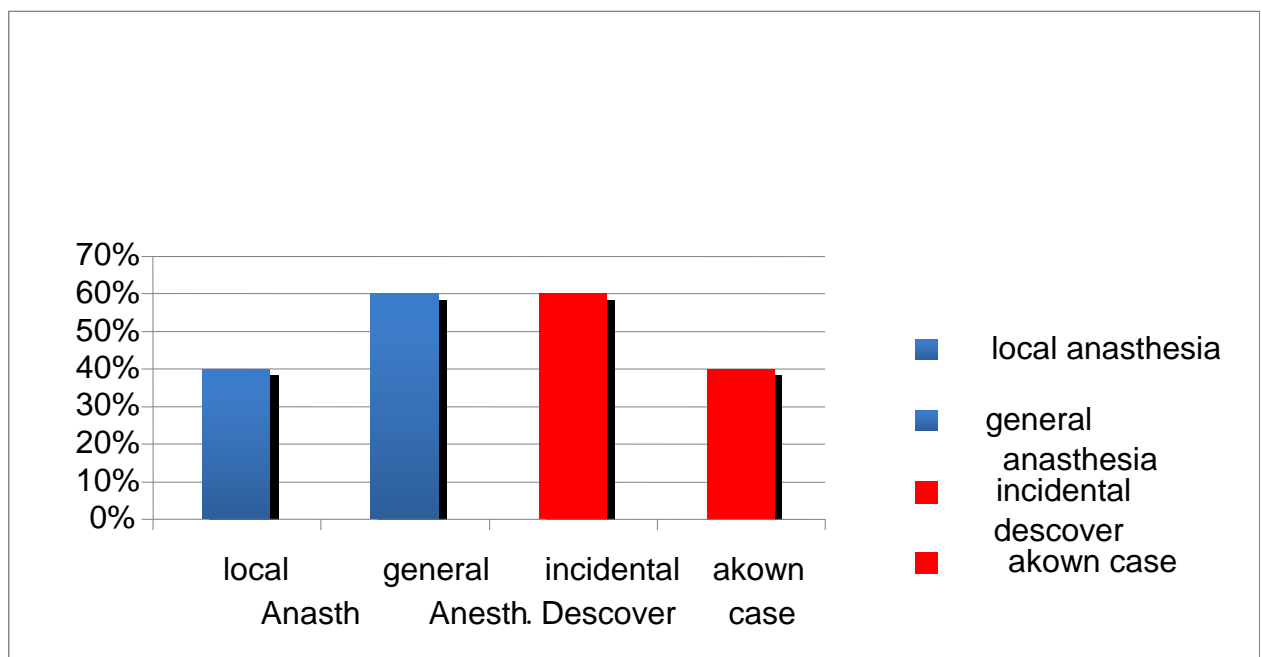
Table 3 : distribution of cases according type of anesthesia,diagnosis,type of hydatid cyst & histopathological study.

A total number of 5 patients with skin hydatid cyst aged between 30-70 years ( mean age 50 years ).  
Male :female ratio 2:3 .

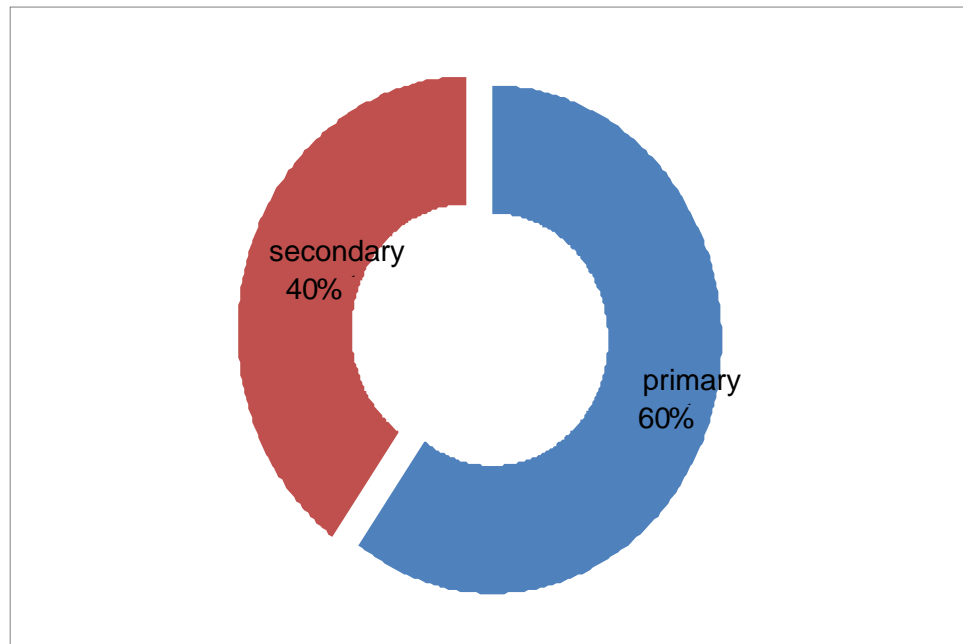


*Fig. 2 Gender distribution*

Three patients diagnosed incidentally during operation & 2 diagnosed preoperatively .  
The study also showed that 40% of male & 60% of female patients.

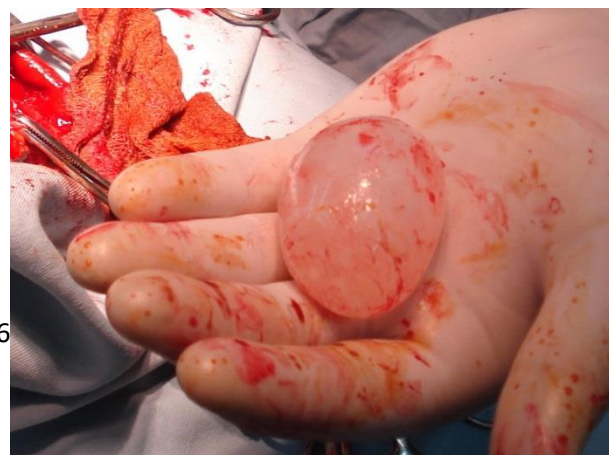
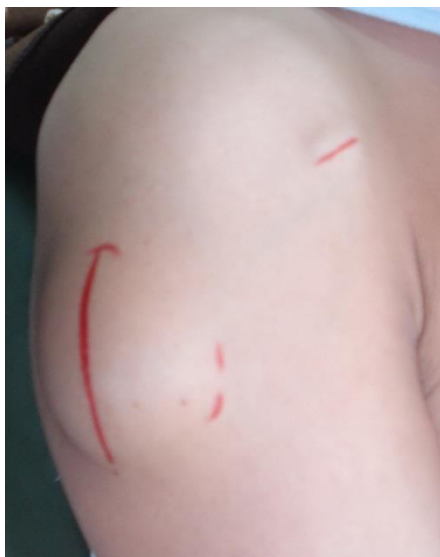
**Fig.3 Type of anesthesia & diagnosis .**



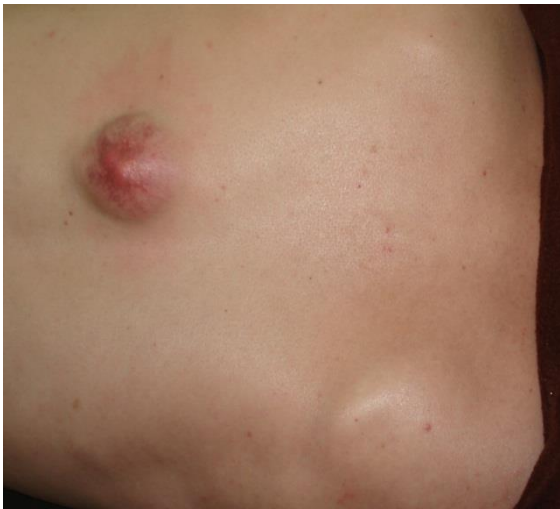**Fig.4 Type of cysts.**

The interesting aspect of 3 cases ( case no.2 , 3 & 5 ) with solitary cysts in skin is the absence of disease in the liver & lungs .

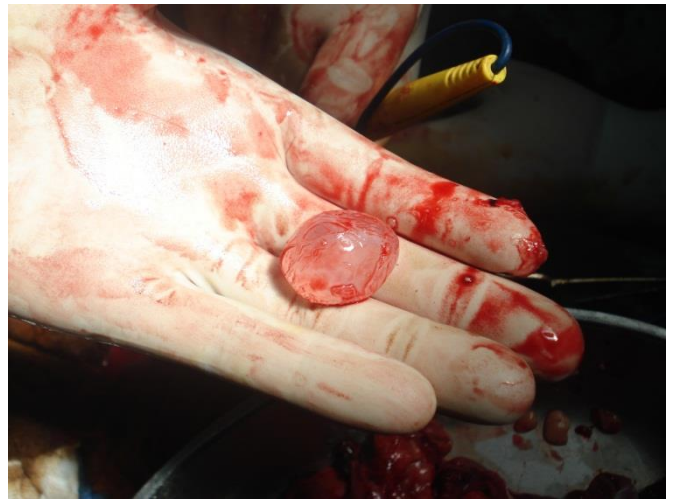



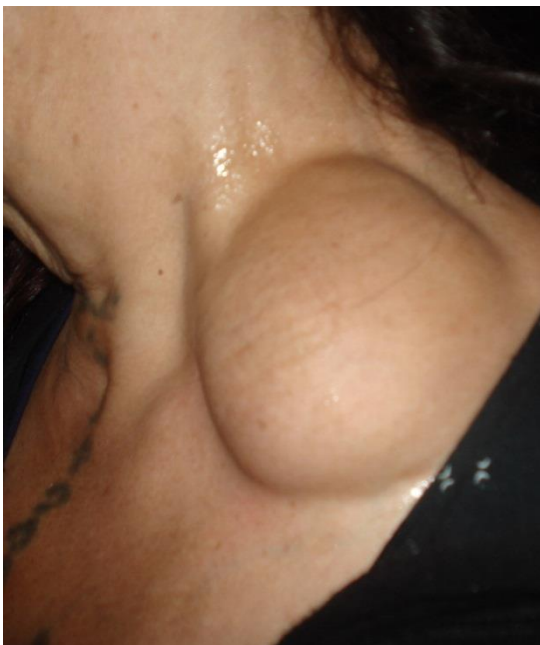
**Figure 5 case no. 1 before surgery**



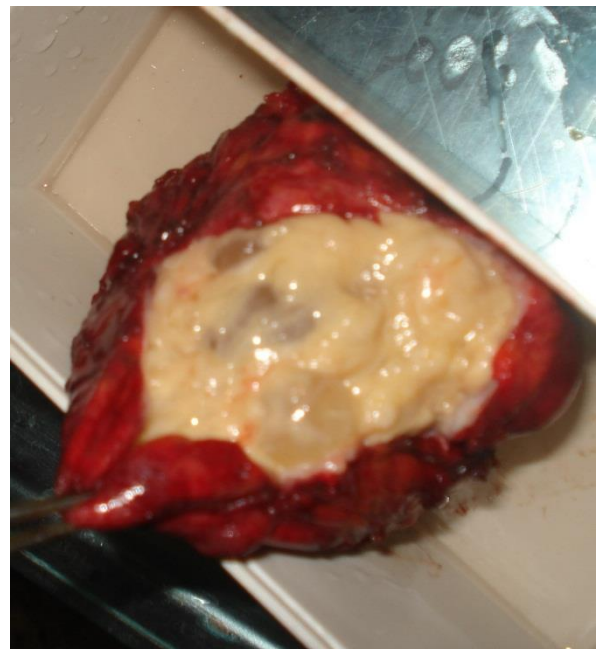
**Figure 6 case no.1 after surgery**



**Figure 8 : case no.2 after surgery**



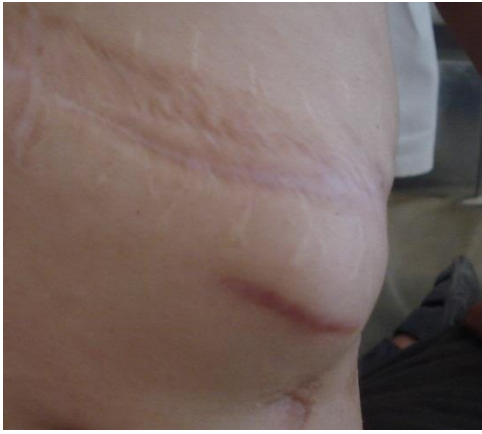
**Figure 7 : case no.2 before surgery.**



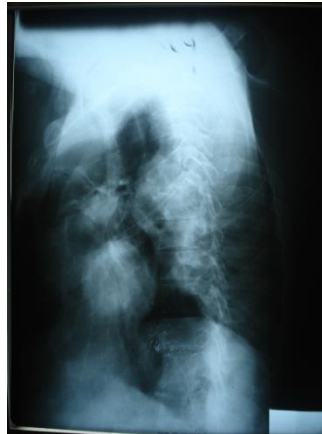**Figure 9 : case no.3 before surgery**

**Figure 10 : case no.3 after surgery**

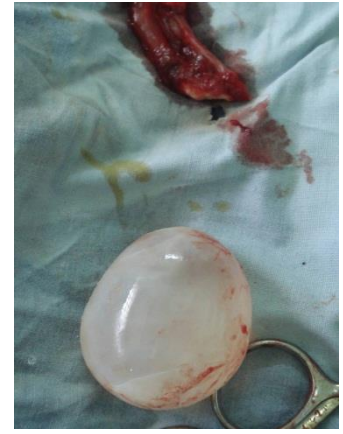



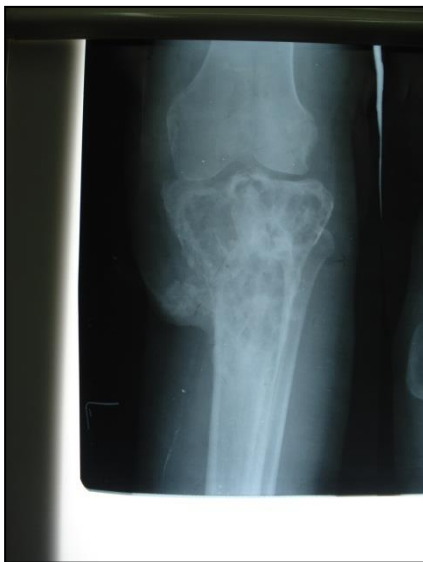**Figure 10 case no.4 before surgery**



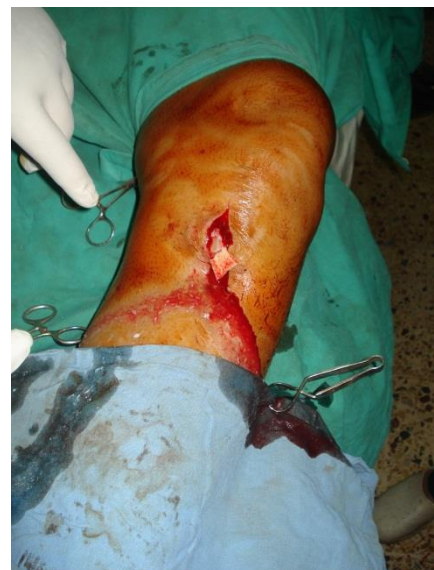**Figure 11 case no.4 chest  
x-ray lateral view**



**Figure 13 case no.4  
after surgery.**



**Figure 14 case no.5 tibia & fibula**



**Figure 15 case no.5 during surgery.  
Involvement with skin involved.**

## Discussion:

Hydatid disease is caused by *Echinococcus granulosus*. The adult parasite ,resides in the intestine of animals such as dogs ,foxes ,jackals ( as definitive hosts ).

Hydatid disease exists all over the world (endemic in the great sheep-rearing countries ) & it is a major health problem & serious public health hazard for the community. In Iraq it is still hyperendemic & is considered to be one of the most serious helmenthic diseases in the country. <sup>4</sup>

The ova ,which are resistant to many environmental conditions ,are excreted in the feces, & ingested by the intermediate hosts ,herbivores & humans .

The ova hatch in the small intestine ,where the parasite penetrate the mucosal wall & reach the liver via the portal vein . The are trapped in the sinusoids, therefore ,the liver is the most frequently involved organ ( 70%) <sup>5</sup>.

The larva which passes through this first filter ,reaches the lung via the right heart, the lung is the second most frequent involved site ( 10-15%). The larva, which passes through this second filter causes hydatid disease in other organs ( 5-15%). <sup>5</sup>

In large series from Greece, the frequency of extrahepatic & extrapulmonary hydatidosis was 9% . <sup>6</sup>

In our cases , the cyst was in the subcutaneous tissue in the shoulder, back of the chest,supraclavicular region, chest wall & left lower limb respectively . In a different series , the frequency of subcutaneous tissue involvement was approximately 2 % . <sup>7</sup>

Most patients were within the age above 30 years ,this goes with the history of infection in teenage & appears after years .

Gender distribution nearly is not different in ratio 2:3 male to female ,more in female may be due to more contact with dogs in the periphery of city.

The interesting aspect of three cases ( case no.2,3 & 5 ) with subcutaneous cysts is the absence of disease in the liver & lung . It is very difficult to explain how the larvae pass through two filter sites & form subcutaneous tissue cysts. Although no route other than the portal route has been proved in humans, it is strongly possible that systemic dissemination via the lymphatic route accounts for cases with subcutaneous tissue cysts in rare sites.

In the other 2 cases ( case no. 1 & 4 ) , with the history of hydatid cyst in other organs ( liver, lung & bone ) recurrent it more than reinfestation

Diagnosis depends on the basis of the history ,radiology , ultrasound finding, serological investigation & incidental discovery. In suspected mass fine needle aspiration biopsy can reveal the early diagnosis by observing the hooklets of the parasite. However, the fine needle aspiration should be avoided because of high risk of anaphlactoid reaction & spillage in suspected lesions . <sup>11</sup>

In our cases there were incidental discover of 3 case & high suspension in other cases.

Upon surgical exploration, the mass was found to be attached to the subcutaneous tissue. the macroscopic appearance suggested a hydatid cyst, perforation was avoided by means of meticulous dissection .because the preoperative diagnosis had not been hydatid disease in 3 cases ( no.1,2,& 3 ), investigation for other organ involvement ( including liver ultrasonography & chest x-ray ) was performed postoperatively & no other focus was found in case no .2 & 3 ,while other focus found in case no.1 ( liver & lung involvement .

Histopathologic examination of the specimen in cases no 2,3,4 & 5 revealed a hydatid cyst .while in case no.1 macroscopic appearance as hydatid cyst & after 6 month through right thoracotomy for lung hydatid cyst confirm the diagnosis.

As in the other hydatid lesions of the body ,surgical removal without spillage is the best method of treatment.<sup>12</sup> Local anesthesia in the 2 cases for diagnostic & therapeutic intervention skin swelling .

Chemotherapy with mebendazole is of limited value ,the most satisfactory treatment is complete excision of the cyst together with its contained parasites.<sup>9</sup>

In case no. 4 in addition to involvement of the subcutaneous of the chest wall ,the other hydatid cyst present in the posterior mediastinum & right upper lobe of lung

In the case no.5 with involvement of fibula & tibia referral the patient to orthopedic surgeon for complete treatment due to involvement of the bone. Complete cure of the osseous involvement is a therapeutic challenge .The disease generally is not curable & recurrence is likely. Surgery is the treatment of choice in osseous Echinococcus . Although it can only eliminate the macroscopic cysts and local recurrence is reported in half of patients , treatment should include a combination of surgery and chemotherapy with albendazole.

Osseous hydatid disease behaves like a locally aggressive relapsing bone tumour.1 Skeletal tumour treatment strategies such as total excision with either biologic or prosthetic Extensive curettage and irrigation followed by filling the cavity with massive allograft chips was performed .<sup>13</sup> cyst fluid is highly allergenic & spillage at surgery may precipitate a type I anaphylactic hypersensitivity reaction .<sup>8 &10</sup> This is a phenomenon which was not encountered in over 5 cases.

The most effective scolicidal agents are: 1.hypertonic saline 2.formalin 3.alcohol 4. 0.5 % silver nitrate solution<sup>2</sup> . In our cases they are not used, & replaced by isolating the area of surgery by iodined packing & meticulous dissection.

Upon questioning the patient reported close contact with dogs for the last five years in cases no. 1 ,3 & case no. 4.

Focuses on other organ involvement on liver & lung due to the most common site of hydatid cyst

An uneventful course was noticed in this study ....No mortality ,with morbidity as skin infection in case no.4 & 5.

The most important issue in cases with cysts in rare sites is whether hydatidosis will develop in the primary sites. these patients should be followed, paying close attention to this possibility .

## **Conclusion & Recommendation :**

1. Hydatid cysts are still an incidental discovery.
2. CXR is still one of the important investigations .
3. It can occur any where in the body.
4. Hydatid disease should be considered in the differential diagnosis of any skin swelling , especially in endemic areas (our country), since this diagnosis may easily be missed unless kept in mind.
5. No drug that can cure the disease ,& surgical intervention is mandatory due to the natural history of hydatid disease.
6. Prophylaxis is the logic approach in the measures including ; dog, sheep & man.

## **References:**

1. Hadni SB,Humbert P,Paintaud G,Auer H,Miguet JP (1996) Skin localization of alveolar echinococcus of liver.J Am Aea Derm. 34:873-877.
2. Nazar B.Elhassani, Spotlights on thoracic surgery .pulmonary hydatid disease part one , 2<sup>nd</sup> edition 2008 p.74-75.
3. Nazar B.Elhassani, postgraduate doctor .pulmonary hydatid disease part one .volume 8,number 1, 1985 p44-49.
4. Nazar B.Elhassani,The neglected disease, Journal of Kurdistan medical society- Kirkuk volume 1, number 2.2004 p6-7.
5. Saidi F,1976.Surgery of hydatid disease .London:WBSaunders Co,31-59.
6. Prousalidis J, Trardinoglouk,Sqouradis L,Katsohis C,Aletras H,,1998.uncommon sites of hydatid disease ,World J.Surg.22:17-22.
7. Chevalier X,Rhamouni A, Bretagne S, Martigny J, Larget-Piet B, 1994. Hydatid cyst of the subcutaneous tissue without other involvement: MR imaging features. AJR 163:645-646 ( online)
8. R.F.Rintoul The liver & the subphrenic space ,Farguharson ,s ,Textbook of operative surgery 1995.415-416.
9. Andrew T.Raftery,Applied basic science for basic surgical training ,alimentary system,2000, 17 p.530.
10. Deve, F De I,echinococcose secondaire.These, Paris,Societe D,Editions Scientifiques.1910
11. Sagin H.B.,Kiroglu Y., Aksoy F. Hydatid cyst of the breast diagnosed by fine needle aspiration biopsy.A case report.Acta Cytol,1994,38: 965-7.) (online)
12. Quedraogo E.G.Le kyste hydatique du sein- Etude de 20 observations. J Gynecol Obstet Biol Reprod (paris), 1986,15:187-94.
13. Arazi M, Erikoglu M, Odev K, Memik R, Ozdemir M. Primary echinococcus infestation of the bone and muscles. Clin Orthop Relat Res 2005;432:234-41.